

Noncontact, Low-Frequency Ultrasound Therapy* for Debridement and Closing of Tunnels in Infected Chronic Wounds

Lisa Buth, PT, WCC; Penny Sacks, PT, WCC; and Ruth Martinez, PT, CWS
Scripps Memorial Hospital, La Jolla California

Introduction

The wound healing process is inhibited by high levels of bacteria in a wound. A locally administered, nontoxic method for controlling bioburden would be of substantial benefit in the treatment of infected, nonhealing wounds. Clinical studies have demonstrated the efficacy of noncontact, low-frequency ultrasound in improving healing rates and time to healing in a variety of chronic wounds.¹ In addition, an antimicrobial effect of noncontact ultrasound was observed in an *in vivo* experiment.²

Case Series

We report the course and outcomes of noncontact, low-frequency ultrasound therapy for debridement and bioburden reduction in 3 infected wounds.

Outcomes

In these challenging wounds, necrotic tissue and bioburden were substantially reduced and tunneling resolved with the use of noncontact ultrasound for debridement.

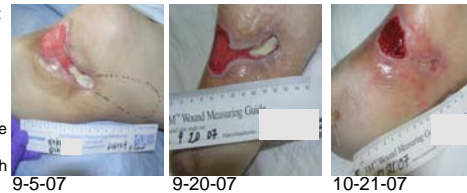¹ Unger P. Low- frequency, noncontact, nonthermal ultrasound therapy: a review of the literature. *Ostomy Wound Manage.* 2008;54(1):57-60.

² Kavros SJ, Schenck EC. Use of noncontact low-frequency ultrasound in the treatment of chronic foot and leg ulcerations: a 51-patient analysis. *J Am Podiatr Med Assoc.* 2007;97(2):95-101.

*MIST Therapy System, Celleration, Eden Prairie Minnesota

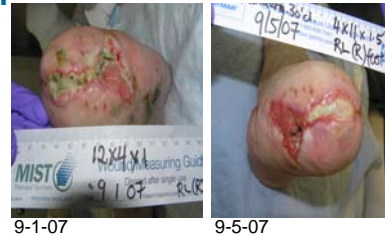Patient #1: Left Knee Trauma Wound

- ❖ 56-year-old diabetic man with an infected traumatic wound (*Acinetobacter baumannii*) to the site of a prior left below-the-knee amputation
- ❖ Medical hx: uncontrolled diabetes mellitus (blood sugars in 400s), peripheral neuropathy, CHF
- ❖ Tunneling (10 cm at 2:00) persisted through 5 weeks of negative pressure wound therapy (NPWT) and VersaFoam; Wound decreased from 52.5 to 39.0 cm² (see table)
- ❖ After 4 weeks of noncontact ultrasound in conjunction with NPWT, tunnel had closed
- ❖ After 8 weeks, wound measured 11.3 cm² (see table)
- ❖ Patient transferred to long-term care facility (NPWT only continued)



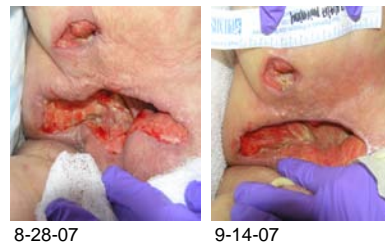
Patient #2: Amputation Incision

- ❖ 45-year-old man with infected wound along incision following transtatarsal amputation; right and left forefoot gangrene
- ❖ Positive culture: *Serratia marcescens*, *Pseudomonas aeruginosa*, multidrug-resistant *Enterobacter cloacae*
- ❖ Medical hx: bacterial endocarditis, sepsis, acute renal failure, multiorgan failure
- ❖ Prior wound care: NPWT, incision & drainage, papain-urea ointment
- ❖ Noncontact ultrasound used to debride wound of necrotic tissue (slough) in preparation for NPWT; Dressing: silver alginate
- ❖ Before and after photos show rapid, substantial decrease in yellow slough and increase in red granulation tissue with 5 consecutive noncontact ultrasound treatments



Patient #3: Perirectal Abscess

- ❖ 81-year-old woman with a peri-rectal abscess positive for *E. coli*.
- ❖ Medical hx: rheumatoid arthritis, severe COPD, endocarditis, abdominal aortic aneurysm, atrial fibrillation, transient ischemic attack
- ❖ After 4 weeks of NPWT, noncontact ultrasound was initiated to debride the wound of yellow slough and increase granulation
- ❖ After 3 weeks of noncontact ultrasound (9 treatments) plus NPWT, yellow slough decreased and granulation increased (see table) despite declining medical status (multiorgan failure and ultimate ICU admission)
- ❖ With noncontact ultrasound, bioburden was effectively controlled in this wound located in a region at high risk for contamination



Time point	Dimensions, cm			Treatment	Tissue color, %			
	Length	Width	Depth		Red	Pink	Yellow	Black
Patient #1								
7-28-07	7	7.5	2	Started NPWT	0	50	50	0
9-3-07	6.5	6	0.7	Added ultrasound	0	50	50	0
10-25-07	2.7	4.2	0.2	NPWT + ultrasound	100	0	0	0
Patient #2								
9-1-07	4	12	1	Started ultrasound	0	50	50	0
9-5-07	4	11	1.5	Stopped ultrasound	60	0	40	0
Patient #3								
Wound 1								
8-28-07	11.8	2.5	3	Added ultrasound to NPWT	0	50	50	0
9-18-07	12.2	2	2.5	Stopped ultrasound 8-14-07	60	0	40	0
Wound 2								
8-28-07	3.5	1.5	1.7	Added ultrasound to NPWT	0	50	50	0
9-18-07	3.5	1.3	1	Stopped ultrasound 8-14-07	60	0	40	0